

LAPAROSTOMY IN PATIENTS WITH ACUTE WIDESPREAD PERITONITIS**V. V. Benedykt, A. M. Prodan, Yu. V. Soroka, V. M. Bahrii**

I. Horbachevsky Ternopil National Medical University of the Ministry of Health of Ukraine

Key words: acute peritonitis, laparostomy, advanced method.**Tayanch so'zlar:** o'tkir peritonit, laparoskopomiya, kengaytirilgan usul.**Ключевые слова:** острый перитонит, лапаростомия, расширенный метод.

Treatment of patients with acute surgical abdominal pathology requires the surgeon to choose the optimal surgical tactics. The aim of the work was to develop criteria for choosing surgical tactics for laparostomy in patients with acute widespread peritonitis (AWP) to improve the results of treatment. 50 clinical records of patients who died of AWP and 131 patients' clinical cases after surgical treatment of AWP were studied. The use of laparostomy in patients with acute peritonitis prevents the development of intra-abdominal hypertension, facilitates aeration of the abdominal cavity, and improves the postoperative period. The proposed method of laparostomy allows monitoring of the condition of abdominal organs after surgery, reducing the number of relaparotomies, and abandoning the use of general anesthesia during the laparotomy closure.

O'TKIR PERITONIT BILAN OG'RIGAN BEMORLARDA LAPAROSTOMIYA**V. V. Benedykt, A. M. Prodan, Yu. V. Soroka, V. M. Bahrii**

Ukraina Sog'liqni saqlash vazirligining I. Horbachevskiy Ternopil milliy tibbiyot universiteti

O'tkir xirurgik qorin patologiyasi bo'lgan bemorlarni davolash xirurgdan optimal jarrohlik taktikasini tanlashni talab qiladi. Ishning maqsadi davolash natijalarini yaxshilash uchun o'tkir tarqalgan peritonit (O'TP) bilan og'rigan bemorlarda laparostomani qo'llash bo'yicha jarrohlik taktikasini tanlash mezonlarini ishlab chiqishdan iborat. O'tkir tarqalgan peritonitdan vafot etgan bemorlarning 50 ta holat tarixi va O'TPni jarrohlik davolashdan so'ng 131 nafar bemorni davolashning klinik holatlari o'rganildi. O'tkir peritonit bilan og'rigan bemorlarda laparostomiyaning qo'llanilishi qorin bo'shlig'i ichki gipertenziyasi rivojlanishiga to'sqinlik qiladi, qorin bo'shlig'ining aeratsiyasini va operatsiyadan keyingi davrning kechishini yaxshilaydi. Laparostomiyaning taklif qilingan usuli operatsiyadan so'ng qorin bo'shlig'i a'zolarining holatini kuzatish, relaparostomiya miqdorini kamaytirish, laparostomiyani yopishda umumiy anesteziyani qo'llashdan voz kechish imkonini beradi.

ЛАПАРОСТОМИЯ У БОЛЬНЫХ ОСТРЫМ РАСПРОСТРАНЕННЫМ ПЕРИТОНИТОМ**В. В. Бенедикт, А. М. Продан, Ю. В. Сорока, В. М. Багрий**

Тернопольский национальный медицинский университет им. И. Горбачевского МЗ Украины

Лечение больных с острой хирургической абдоминальной патологией требует от хирурга выбора оптимальной хирургической тактики. Цель работы — разработать критерии выбора хирургической тактики наложения лапаростомы у больных с острым распространенным перитонитом (ОРП) для улучшения результатов лечения. Изучены 50 историй болезни больных, умерших от ОРП, и клинические случаи лечения 131 больного после оперативного лечения ОРП. Применение лапаростомии у больных с острым перитонитом предотвращает развитие внутрибрюшной гипертензии, способствует аэрации брюшной полости, улучшает течение послеоперационного периода. Предлагаемый способ лапаростомии позволяет следить за состоянием органов брюшной полости после операции, уменьшить количество релапаростом, а при закрытии лапаростомы отказаться от применения общей анестезии.

Introduction. Treatment of patients with acute surgical abdominal pathology requires the surgeon to choose the optimal surgical tactics. The problem of choosing the best method of completion surgery in patients with AWP is one of the most debatable issues in emergency surgery. The reason for unsatisfactory results of such patients' surgical treatment may be the development of the intra-abdominal hypertension with the following development of multiple organ failure [6, 4]. Thus, the study of mortality causes in patients with AWP and methods of completion surgery in such patients is quite relevant and served as a basis for choosing the topic of this work.

The aim of the work was to develop criteria for choosing surgical tactics for laparostomy in patients with AWP to improve the results of treatment.

Materials and methods. We conducted a retrospective analysis of 50 medical records of patients who died of AWP. The results of 131 patients' treatment after surgical cure of AWP were studied in clinical settings. The common set of studies included the determination of the Mannheim index of peritonitis [7], leukocyte index of intoxication [5], comorbidity index [3], and the degree of operational and anesthesia risk on the ASA scale [1]. In addition, Measurements of intra-abdominal pressure were performed according to I. Kron et al. (1998), M. Cheatham et al. (1998).

Research results and their discussion. A retrospective analysis of medical records of patients who died of AWP indicated that the cause of death in 41 patients (82.0 %) were multiple

organ dysfunction syndrome, toxic shock syndrome; pulmonary embolism - in 5 (10.0%) cases, cerebral pathology – in 3 (6.0%), progression of pulmonary heart failure with the development of DIC syndrome – in 1 patient (2.0%). There were 4 patients (8.0%) with the first stage of peritonitis out of all cases (тут, напевно, мало б бути cases) in this group; with the second - 18 (36.0%); with the third - 28 (56.0%). The Mannheim index of peritonitis averaged 27.34 points.

It was found that at admission there was no digestive tract (DT) motility in 36 (72.0%) patients, suppression of DT motility- in 14 (28.0%) cases; while at the end of treatment - in 41 (82.0%) patient is DT motility was absent, in 6 (12.0%) patients - it was suppressed and in 3 (6.0%) cases – it was normal. Thus, DT motility is usually absent along with the progression of multiorgan failure. Its absence contributes to the deepening of the manifestations of dysfunction of organs and systems of the patient. The fatal outcome in 32 operated patients occurred in the first two days in 31 (60.0%) cases, for 4-5 days - in 10 (20.0%) cases.

Thus, mortality in patients with AWP occurs after surgery, usually from multiple organ failure due to intoxication, mostly caused by a functional obstruction of the DT and possibly an increase in intra-abdominal pressure. In the later period (in 7 cases - 14.0%) lethal outcome occurred because small bowel intubation was performed in only 13.89% of operated patients, while the end of the operation in the form of laparostomy was performed in 10 (19.44%) cases.

Laparostomy was used in 18 (13.74%) patients with AWP at the end of laparotomy. This method was used in 13 cases during primary surgery, in 5 cases - during relaparotomy in patients with postoperative peritonitis. In 7 cases we openly performed intubation of DT with enterostomy after forced resection of the distal organ and according to our proposed method [2] in case of ineffectiveness of closed antegrade decompression in patients with AWP during relaparotomy for unresolved peritonitis.

The level of intra-abdominal pressure has a significant impact on the development of multiple organ failure. In determining the value of this indicator in the uncomplicated course of AWP, we obtained the following data: 1st day after surgery - 12.75 ± 2.12 mm Hg., when restoring the motor-evacuation function DT - 8.50 ± 1.40 mm Hg. ($p < 0.05$). Determination of intra-abdominal pressure is a prognostic criterion that complements the assessment of the postoperative period.

We offer an advanced method of laparostomy (Fig.1). Before suturing the abdominal cavity and after its drainage, perforated smooth film (3) was applied to the large omentum (4) or, in its absence, to the loop of the small intestine (5). On top of the film was laid a barrier of 6-8 PVC tubes (2). Such tubes were stitched with synthetic thread (№ 5-6) in three places (1) before. With the help of these threads, the PVC tubes were fixed to the abdominal wall by stitching the anterior abdominal wall from the middle outwards. The threads were tied with a knot. The length of the PVC tubes should be bigger than the length of the laparotomy wound by 3-5 cm. Gauze wipes soaked in 0.05% chlorhexidine solution were placed between the edges of the skin.

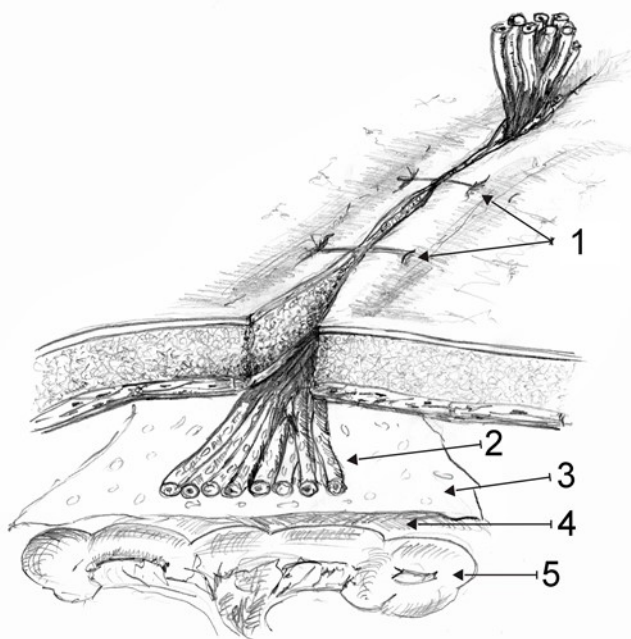


Fig. 1. The general scheme of the laparostomy.

PVC tubes should be bigger than the length of the laparotomy wound by 3-5 cm. Gauze wipes soaked in 0.05% chlorhexidine solution were placed between the edges of the skin.

According to our data, intra-abdominal pressure averaged (12.52 ± 3.38 mm Hg) in patients with AWP, even in the presence of postoperative paresis with laparostomy. There was a restoration of motility of the small intestine after 2-3 days, which allowed to prescribe early enteral nutrition and reduce the level of intoxication.

Closure of the laparostomy was performed gradually over 7-10 days after surgery with a satisfactory course of the disease (according to clinical, sonographic criteria) by dissection of synthetic fibers (1), gradual removal of

2-3 PVC tubes per day, and perforated film (3) by intraoperative superimposed ligature, which she was stitched during the operation.

Given our experience in the treatment of patients with AWP indications for the use of laparostomy are the presence of acute purulent widespread peritonitis, incomplete decompression of the DT during the operation because of technical difficulties, unpredictability in the tightness of the formed anastomosis, decompensated functional state of the patient, obesity, the difficulty of completing the operation by suturing a laparotomy wound, and the possibility of increased intra-abdominal pressure. The use of the proposed method allowed to reduce the number of relaparotomies to complete the laparostomy under the condition of AWP with the favorable course in patients, which significantly improved the results of surgical treatment of these patients.

Conclusions.

1. The use of laparostomy in patients with acute peritonitis prevents the development of intra-abdominal hypertension, facilitates aeration of the abdominal cavity, and improves the postoperative period.

2. The proposed method of laparostomy allows monitoring of the condition of abdominal organs after surgery, reducing the number of relaparotomies, and abandoning the use of general anesthesia during the laparotomy closure.

3. The use of laparostomy in patients with acute peritonitis significantly improves the results of surgical treatment.

References:

1. Doyle, D. J., & Garmon, E. H. (2017). American Society of Anesthesiologists classification (ASA class).
2. Dzubanovsky, I. Y., Bedykt, V. V., & Prodan, A. M. (2020). Laparostoma in a surgical treatment of acute obstruction of the small intestine. *Art of Medicine*, 74-78.
3. Hall, S. F. (2006). A user's guide to selecting a comorbidity index for clinical research. *Journal of clinical epidemiology*, 59(8), 849-855.
4. Hunter, J. D., & Damani, Z. (2004). Intra-abdominal hypertension and the abdominal compartment syndrome. *Anaesthesia*, 59(9), 899-907.
5. Ostrovskii, V. K., Alimov, R. R., Mashchenko, A. V., Semenova, O. P., & Kurapova, M. I. (2003). Normal parameters of leukocyte index of intoxication. *Klinicheskaia Laboratornaia Diagnostika*, (1), 45-46.
6. Pereira, B. M. (2019). Abdominal compartment syndrome and intra-abdominal hypertension. *Current Opinion in Critical Care*, 25(6), 688-696.
7. Qureshi, A. M., Zafar, A., Saeed, K., & Quddus, A. (2005). Predictive power of Mannheim peritonitis index. *Journal-College Of Physicians And Surgeons Of Pakistan*, 15(11), 693.